

PATIENT

Flynn Korin

SPECIES

Canine

BREED

Border Collie Mix

SEX

MN

AGE

2015

WEIGHT

53.8

INTERPRETED BY

R. McKenzie Daniel,
 DVM, DABVP
 (Canine and Feline)

IMAGING PERFORMED BY

Rebekah Jakum, CVT
 ARDMS/RVT

HOSPITAL NAME

North Saucon Animal
 Hospital

REFERRING VET

Betz

INVOICE

24017

DATE

02/27/2026

PRESENTING CLINICAL SIGNS

- Chronic liver elevations
- PU/PD
- hypothyroid
- thyrotabs .6 bid

ULTRASONOGRAPHIC EXAMINATION OF THE ABDOMEN

Urinary System

The urinary bladder, trigone, cystourethral junction, and visible pelvic urethra to a depth of 3 cm exhibited normal thickness and tone. Anechoic urine was present in the lumen with no evidence of urine/lumen sediment, mineral, or calculi. The ureteral papillae were normal. The ureters were not visible which is normal. No evidence of inflammatory or neoplastic changes was noted.

Normal size and margination were present in the kidneys. A normal 1:3 cortex / medulla ratio was maintained. The medulla and cortices were uniform in texture with some increased echogenicity and mild loss of corticomedullary symmetry and definition expected for the age of the patient. No evidence of pelvic dilation was present. Bilateral discreet hyperechoic cortical foci was present which may indicate areas of fibrosis or mineralization. The left kidney measured 7.0 cm in length. The right kidney measured 6.8 cm in length.

The area of the aortic trifurcation was free of pathology.

The residual prostate appeared normal and free of pathology.

Adrenal Glands

The left adrenal gland was uniform in size and contour with a uniformly hypoechoic parenchyma. The left adrenal gland measured 0.72 cm width at the caudal pole. The right adrenal gland was uniform in size and contour with a uniformly hypoechoic parenchyma. The right adrenal gland measured 0.51 cm width at the caudal pole.

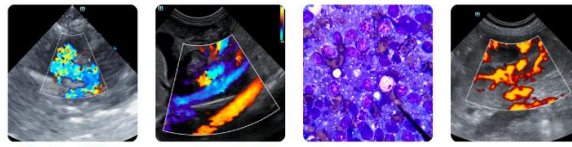
Spleen

The spleen exhibited a finely textured and homogenous parenchyma which was hyperechoic to the liver and renal cortical parenchyma. Areas of mild asymmetrical hyperechoic medial capsule were present suggestive of mild benign fibrosis. The splenic vasculature at the hilus was normal in volume with no evidence of congestion or thrombosis. Acute to chronic inflammatory, neoplastic, or benign parenchyma changes were not noted.

Liver/Gallbladder

The liver presented enlarged in size. The parenchyma of the liver was subjectively normal in echogenicity compared to the spleen and renal cortices. The liver parenchyma was uniform with a mildly coarse echotexture. The capsule of the liver was symmetrically rounded to mildly swollen in margination. The hepatic and portal vasculature were normal in appearance without signs of congestion. The gallbladder was non-distended in size with moderate, gravity dependent to congealed, non-organized variably hyperechoic debris. The cystic and common bile ducts were normal.

Gastrointestinal



PATIENT

Flynn Korin

SPECIES

Canine

BREED

Border Collie Mix

SEX

MN

AGE

2015

WEIGHT

53.8

INTERPRETED BY

R. McKenzie Daniel,
DVM, DABVP
(Canine and Feline)

IMAGING PERFORMED BY

Rebekah Jakum, CVT
ARDMS/RVT

HOSPITAL NAME

North Saucon Animal
Hospital

REFERRING VET

Betz

INVOICE

24017

DATE

02/27/2026

The stomach presented intact wall layering with a normal wall layer ratio. The lumen of the stomach was empty with no signs of ileus, obstruction or foreign material.

The small intestine presented intact wall layering with 1:3 muscularis/mucosa ratio. The lumen of the small intestine was empty with no signs of mechanical/metabolic ileus, obstruction or foreign material.

Normal visible colon wall layers were present with apparent formed feces in lumen.

Pancreas

The parenchyma of the left limb, body and right limb of the pancreas presented isoechoic to the adjacent omental fat. A normal curvilinear capsule contour of the pancreas was present. The visible pancreatic duct was normal. No signs of active inflammation or neoplastic disease was evident.

Free Abdomen

No omental masses, overt lymphadenopathy or peritoneal effusion was present.

ULTRASONOGRAPHIC FINDINGS

Primary

- Hepatopathy - suggestive of benign criteria/ vacuolar hepatopathy pattern
- Congealed non-organized gallbladder debris - not consistent with mature mucocele
- Normal bilateral adrenal glands
- Mild chronic renal changes

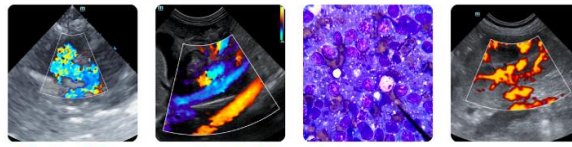
Secondary

- Mild benign splenic medial capsule fibrosis

INTERPRETATION OF THE FINDINGS & FURTHER RECOMMENDATIONS

Assuming normal clotting status and using a 25g needle, a hepatic FNA for screening cytology could be considered primarily to assess for non-obvious inflammatory criteria. No evidence of hepatic neoplastic criteria, which is thought less likely. Although no evidence of adrenal pathology, adrenal screening or workup is warranted if clinical signs consistent with Cushing's syndrome are present.

Hepatosupportive medications including Denamarin and ursodiol may prove beneficial. Renal staging to include urine C/S and protein: creatinine ratio on sterile urine sample is suggested if not recently done.



PATIENT

Flynn Korin

SPECIES

Canine

BREED

Border Collie Mix

SEX

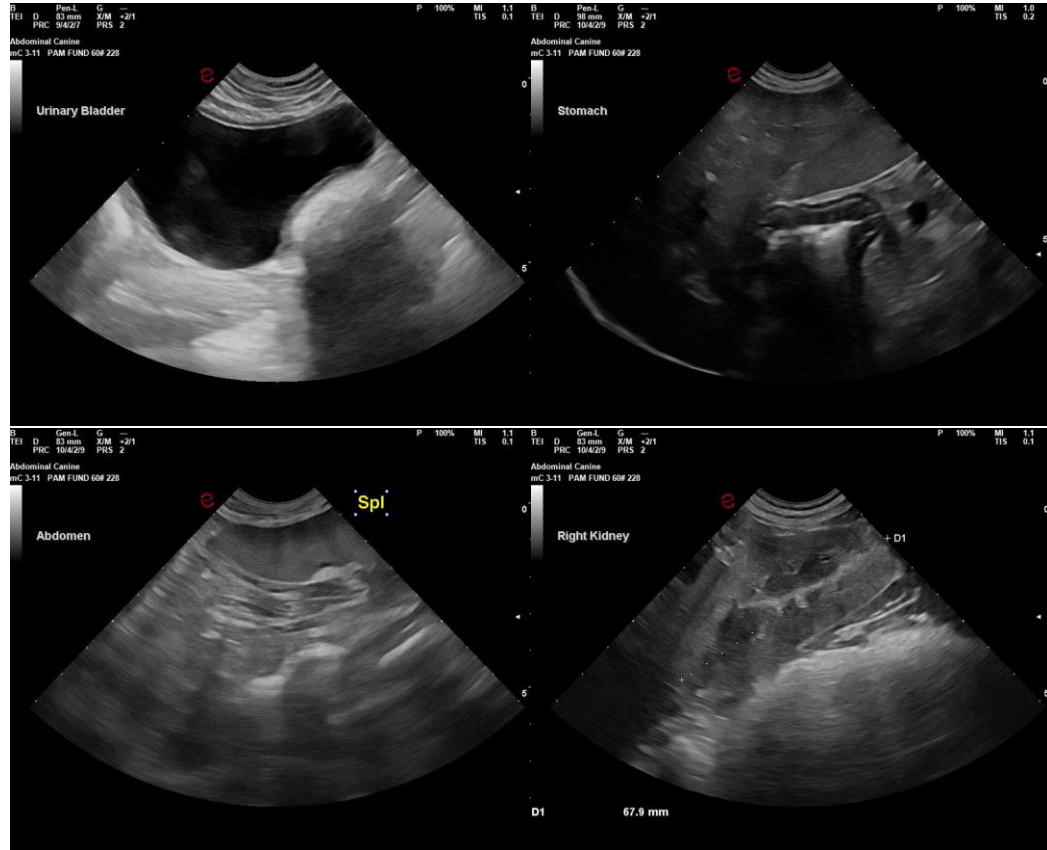MN

AGE

2015

WEIGHT

53.8



INTERPRETED BY

R. McKenzie Daniel,
 DVM, DABVP
 (Canine and Feline)

IMAGING PERFORMED BY

Rebekah Jakum, CVT
 ARDMS/RVT

HOSPITAL NAME

North Saucon Animal
 Hospital

REFERRING VET

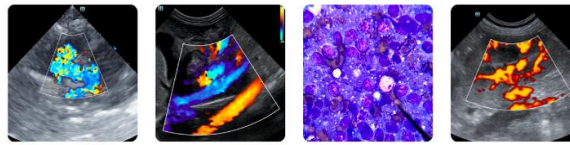
Betz

INVOICE

24017

DATE

02/27/2026



PATIENT

Flynn Korin

SPECIES

Canine

BREED

Border Collie Mix

SEX

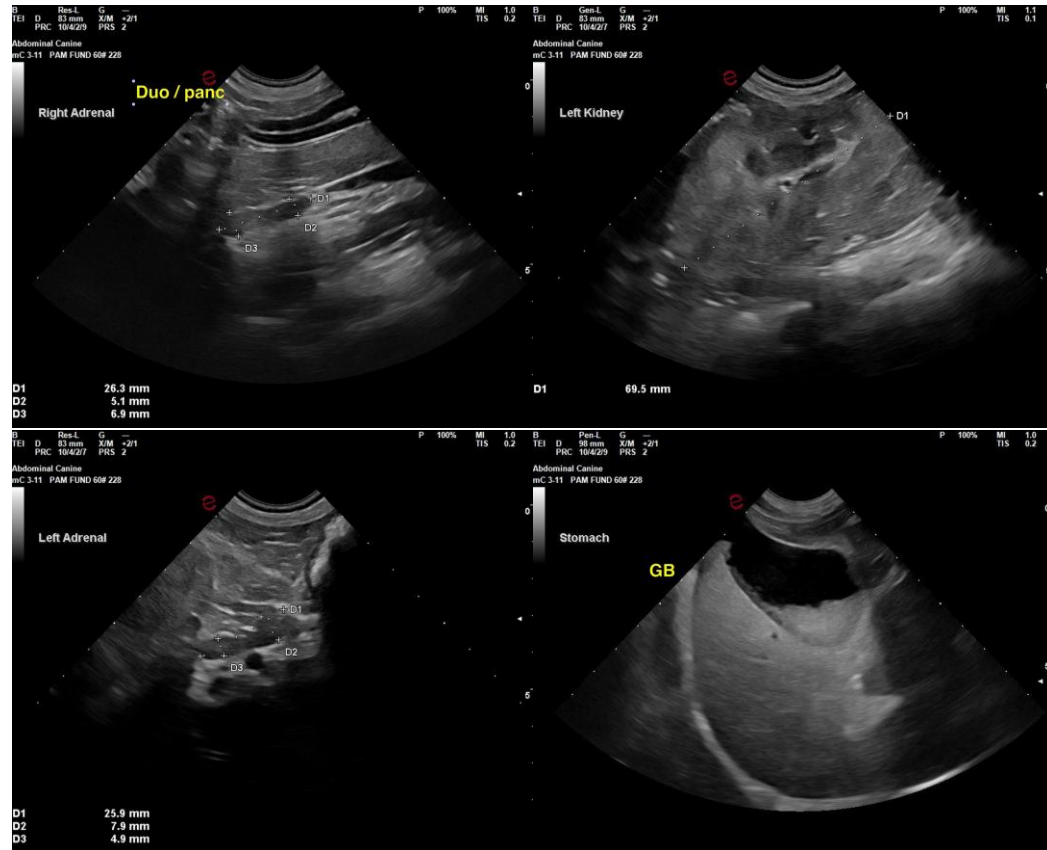
MN

AGE

2015

WEIGHT

53.8



INTERPRETED BY

R. McKenzie Daniel, DVM, DABVP
 (Canine and Feline)

IMAGING PERFORMED BY

Rebekah Jakum, CVT
 ARDMS/RVT

HOSPITAL NAME

North Saucon Animal Hospital

REFERRING VET

Betz

INVOICE
 24017

DATE
 02/27/2026

The information and recommendations provided are based on the images presented by the referring veterinarian/sonographer. No evaluation can be communicated regarding pathology that was not visible in the image/video clips provided.

Thank you for this referral. If the clinical or image interpretation does not parallel your findings or if I can be of any further assistance, please contact me.

R. McKenzie Daniel, DVM, DABVP (Canine/Feline Practice)
info@sonopath.com